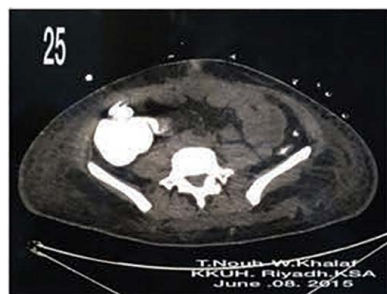
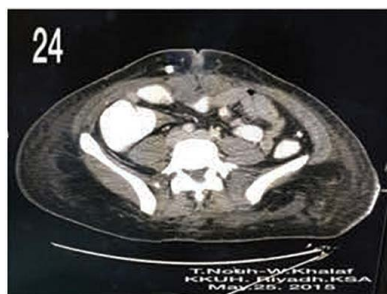
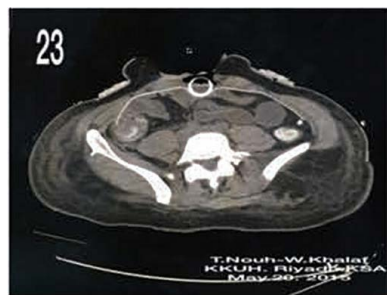
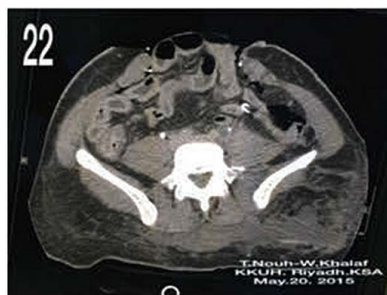Below is a sequence of CT scans – Pre-installation of ABRA (22), ABRA installed (23), Delayed primary closure (24), 2 weeks post delayed primary closure (25).



# **ABRA Abdominal Wall Closure** **SMI Case No. 004**

Courtesy of:

**Dr. Thamer Nouh**  
**Ass. Professor and Consultant Surgeon**  
Head of Trauma and Acute Care Unit  
King Khalid University Hospital  
Riyadh, Saudi Arabia

**Dr. Walid Khalaf**  
**Cl. Ass. Professor and Consultant Surgeon**  
Trauma and Acute Care Unit  
King Khalid University Hospital  
Riyadh, Saudi Arabia



Southmedic Inc.  
50 Alliance Blvd., Barrie, ON L4M 5K3  
www.dynamicissuesystems.com  
contactus@southmedic.com

1-800-463-7146 Toll free in North America  
1-705-726-9383  
1705-728-9537 Fax  
ISO 13485

PO168

## Abdominal Wall Closure Case Study

King Khalid University Hospital

SMI Case # 004

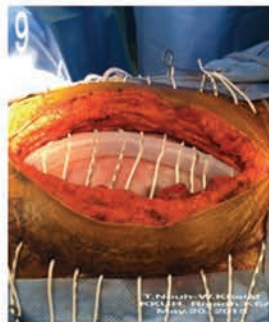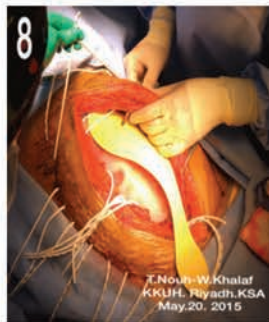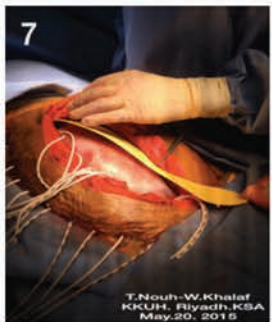
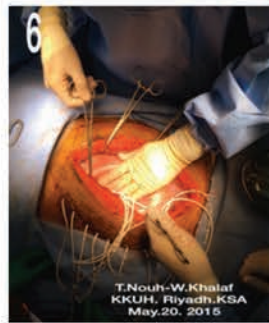
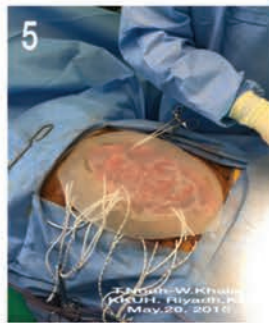
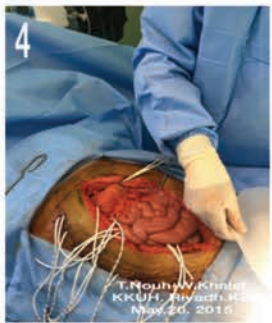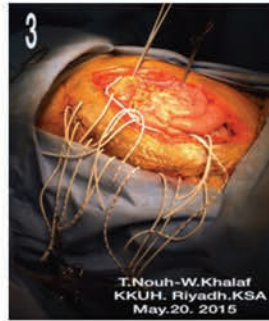
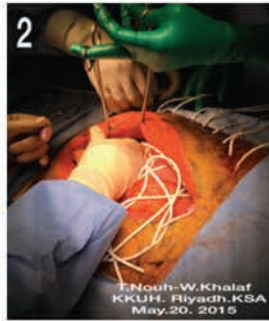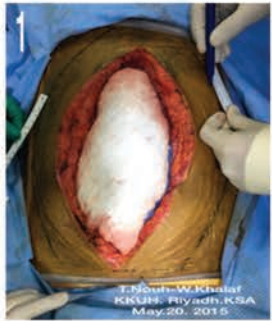# DYNAMIC TISSUE SYSTEMS™

Another **Southmedic** Solution

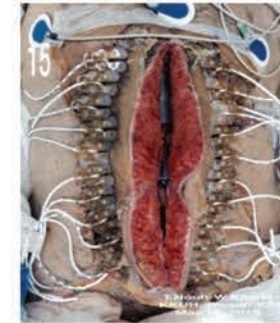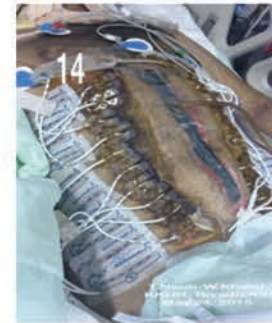Southmedic Inc. 50 Alliance Blvd., Barrie, ON L4M 5K3  
www.southmedic.com contactus@southmedic.com  
1-800-463-7146 Toll free in North America 1-705-726-9383



Case study of a 24 year old male involved in an MVA, sustaining head, thoracic and abdominal trauma. Emergency laparotomy was performed and the wound was kept open and packed for 48 hours. Retracted wound measured 32 x 13 cm. ABRA Abdominal closure system was installed (Pic. 1-12).



The 'Move' and elastomer adjustments were performed daily at bedside. Post-op day 3, satisfactory midline advancement was achieved to permit delayed primary closure. (Pic. 14/15)



Day 4 Post-op, the patient was prepared for a last abdominal exploration and delayed primary closure.

Day 5 Post-op, a tension free full thickness abdominal wall closure was performed. (Pic. 16-21).

