

Sternotomy Closure Case (After Dehiscence)

Case No. 005
ABRA® Dynamic Wound Closure

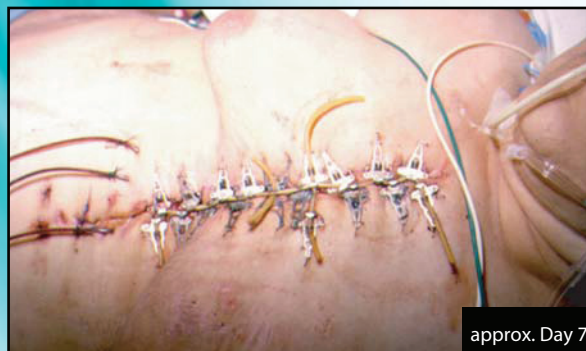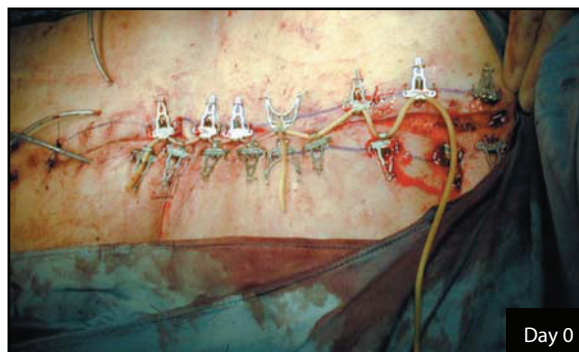
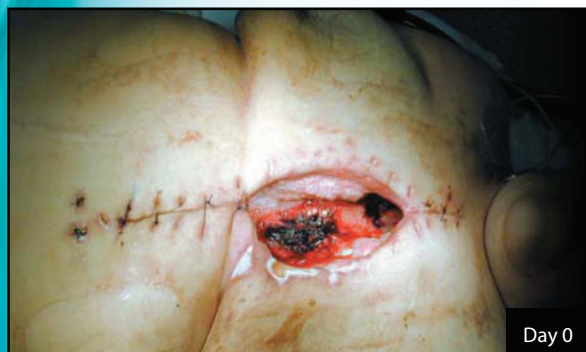History

This sixty-five year old woman developed a post-sternotomy wound infection. She was diabetic and on steroids. Debridement and closure failed and the retention sutures cut through the wound margins at several points, partially complicated by the weight of large, pendulous breasts creating tension across the wound.

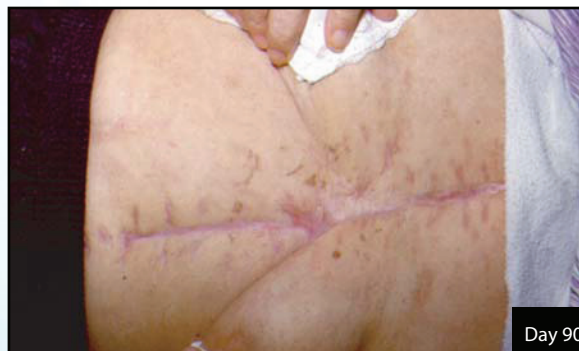Treatment

Closure was accomplished with bilateral pectoral flaps. The skin was thin, friable and ischemic to the extent that conventional closure would likely dehisce again. The Canica Wound Closure System was installed, pulling the wound tightly together after about forty five minutes. The wound healed except for a superficial ulcer 3.5 x 1 mm centrally on the left side at the point where a retention stitch had originally pulled through. This was left to heal by secondary intention.

The system was left in place for approximately twenty one days, and removed in the outpatient department under local anesthesia prior to release. No other closure was required.



Original wound margins re-approximated and stable.



Completely granulated and stable, skin is beginning to re-model.