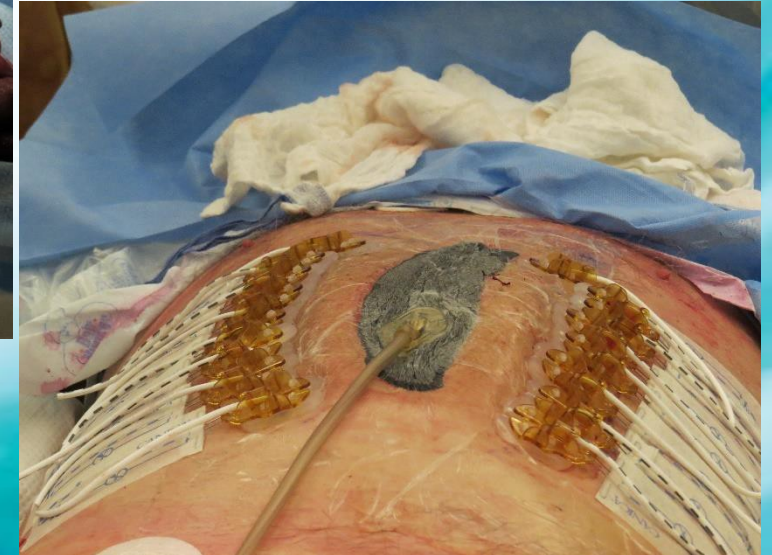
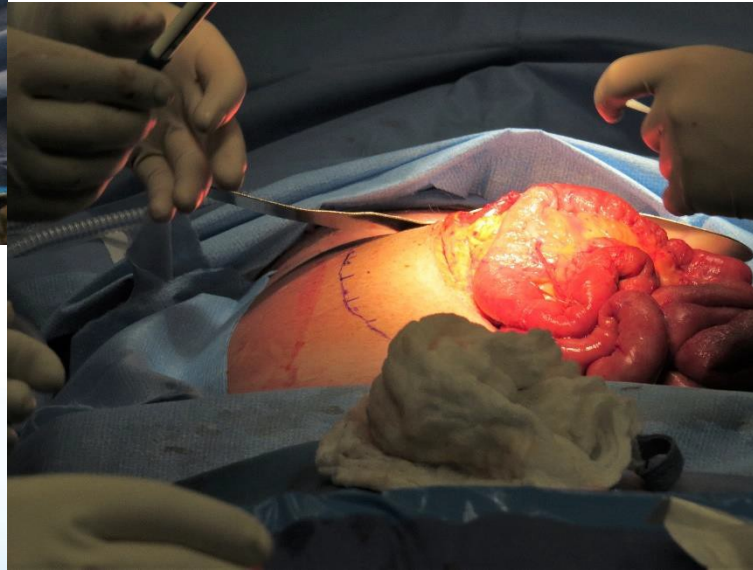
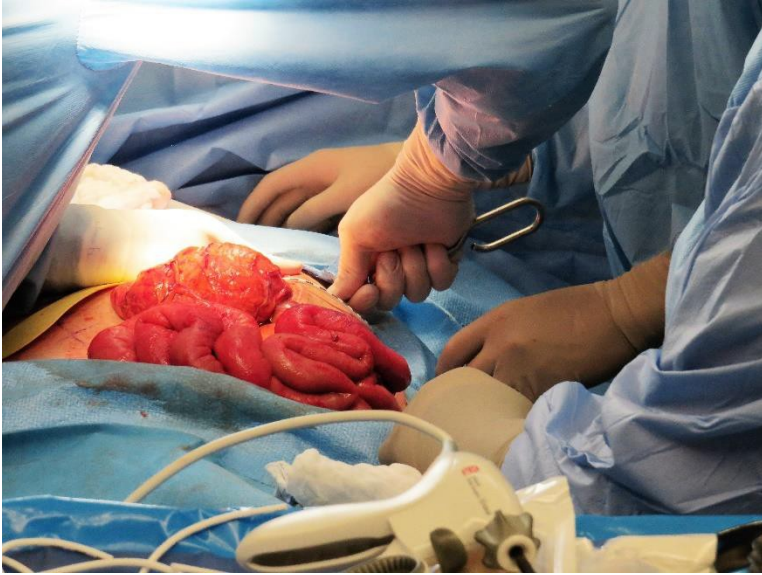

# ABRA ABDOMINAL CASE STUDY, AUGUST, 2015

## BRITISH COLUMBIA, CANADA

- This is a 70 yr old male with Leukemia who had to have an emergency Splenectomy and was left with a retracted abd wound. After a week of NPWT the surgeon elected to install an ABRA Abd.
- Bedside adjust of elastomer and diligent performance of the 'Move' resulted in full layer closure 8 days post-ABRA installation.

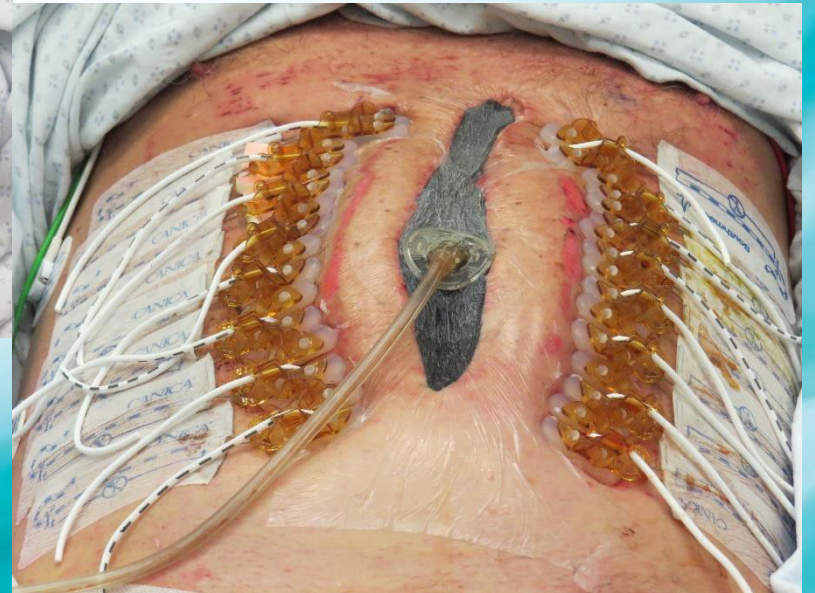
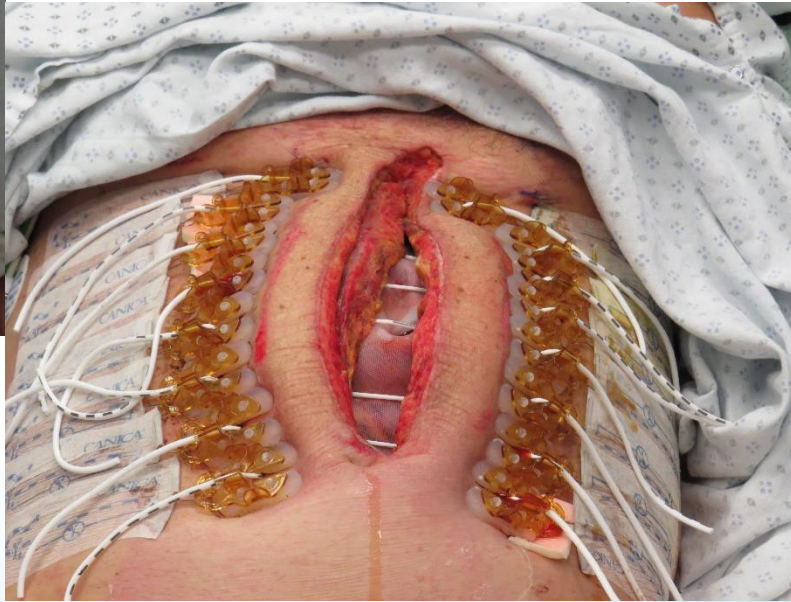
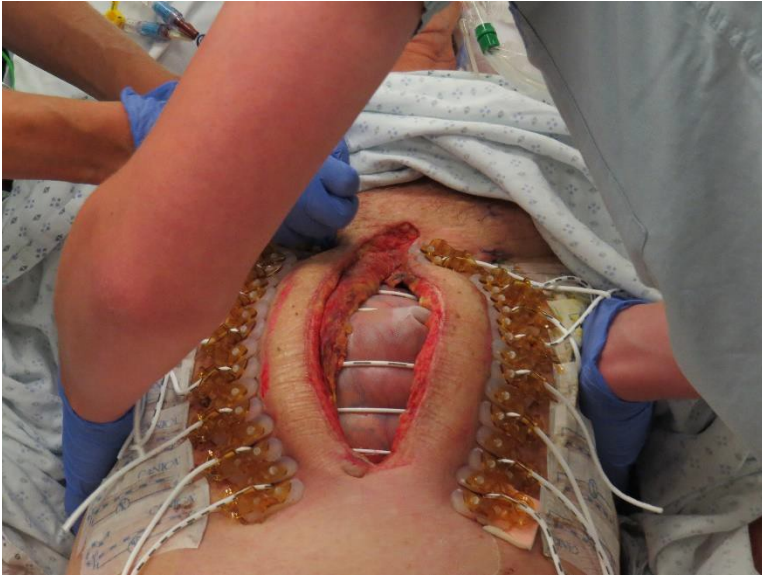# ABRA INSTALLATION AUGUST 17TH



DYNAMIC TISSUE SYSTEMS™

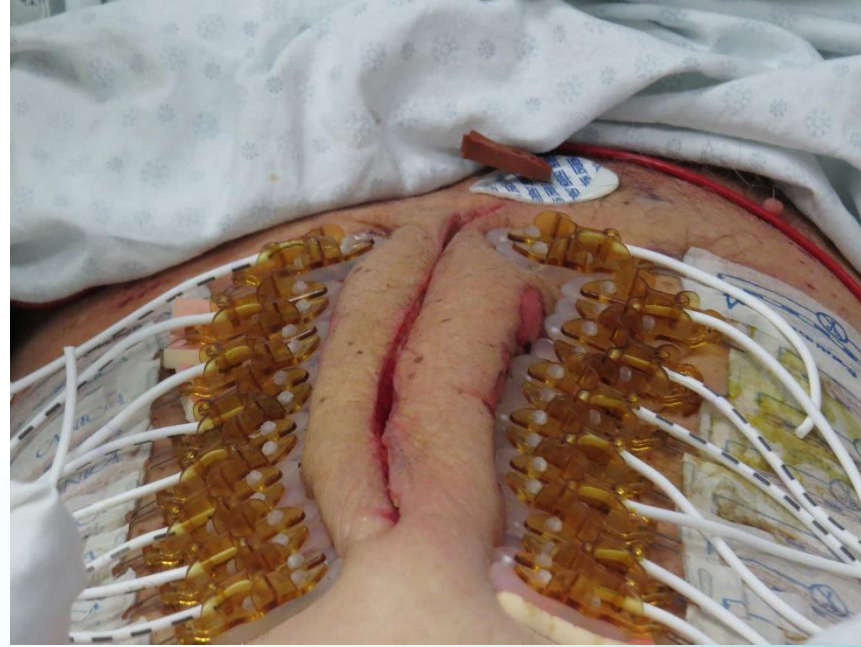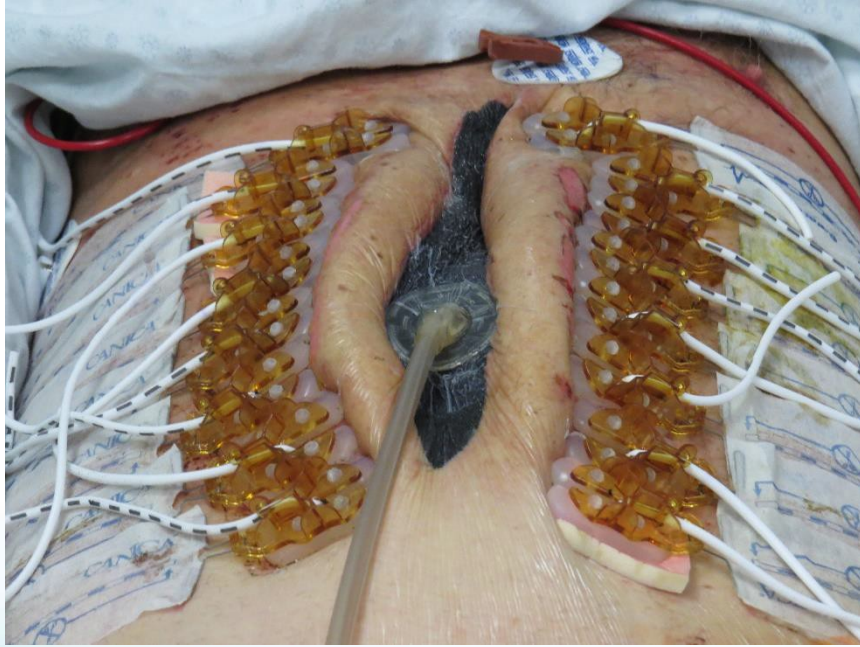


# ABRA ADJUSTMENT DAY 3 POST INSTALLATION





# ABRA ADJUSTMENT DAY 6 POST INSTALLATION





# CLOSURE DAY 8 POST INSTALLATION

