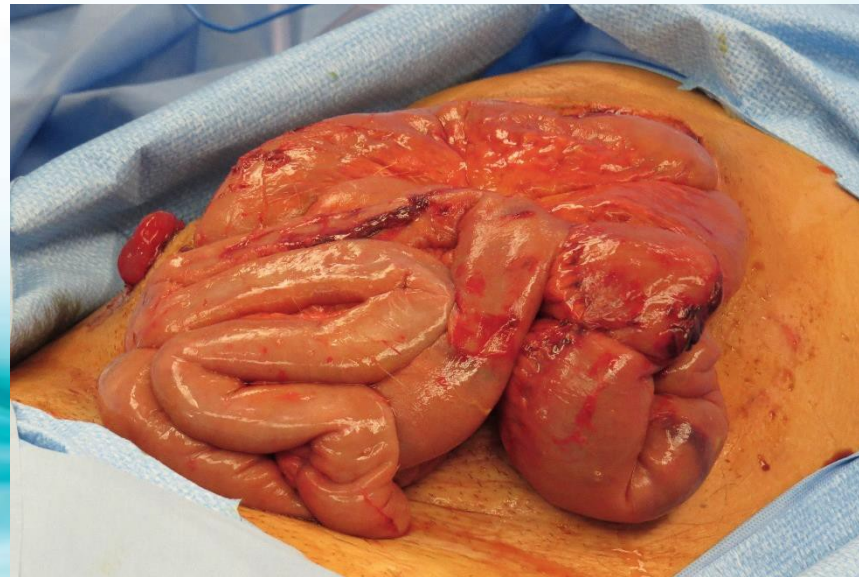
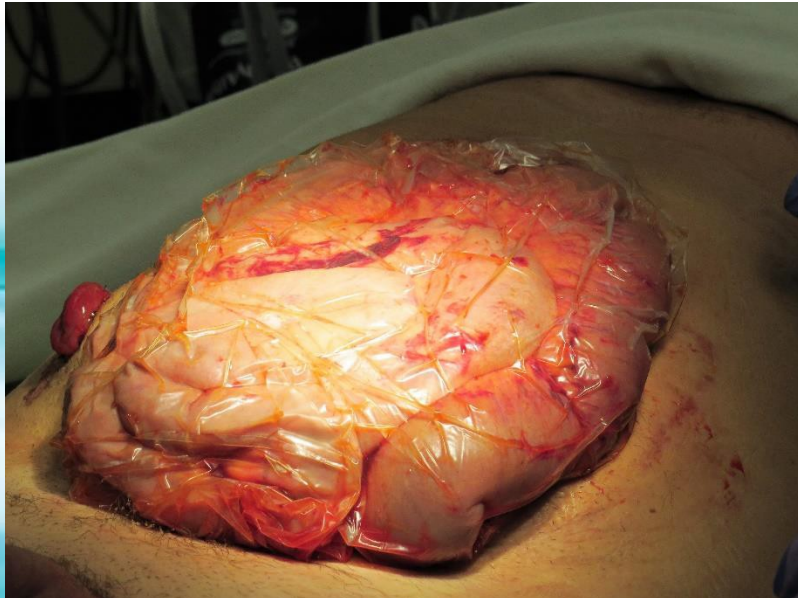
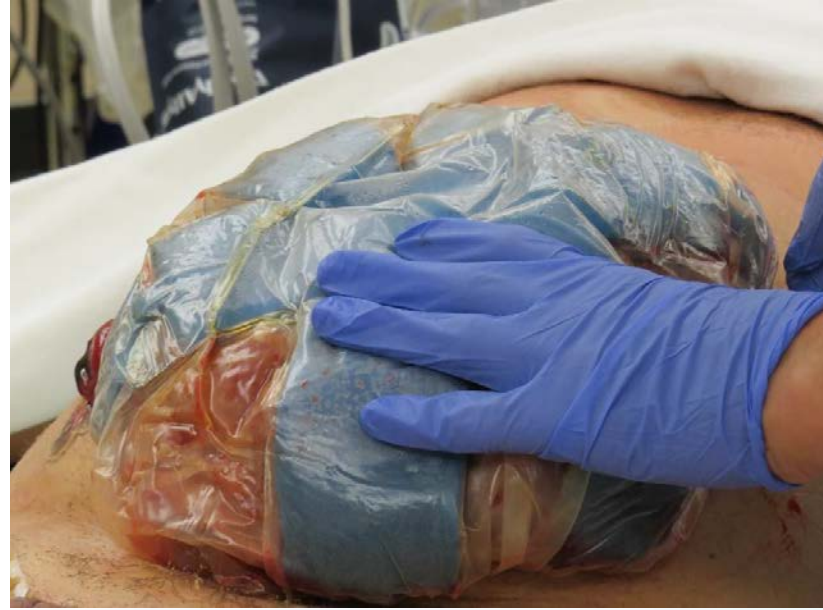
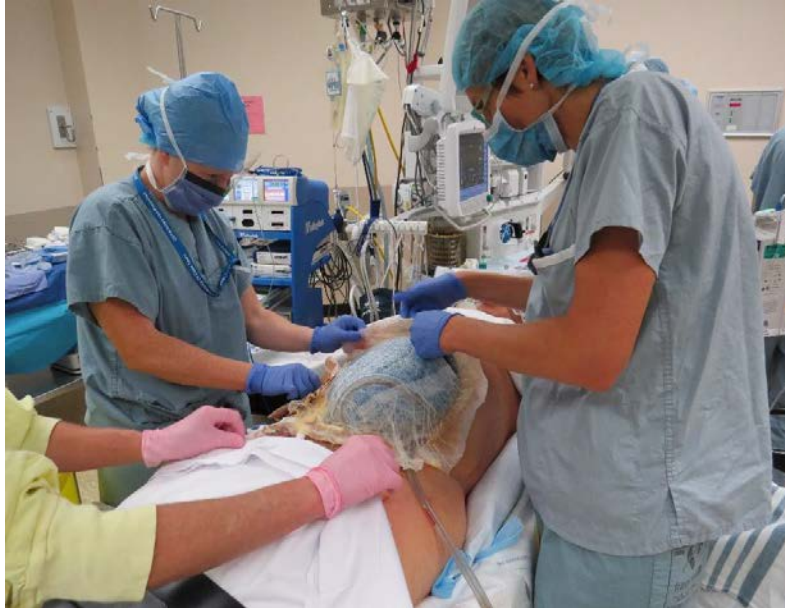
ABRA ABDOMINAL CASE STUDY, AUG – SEP 2015

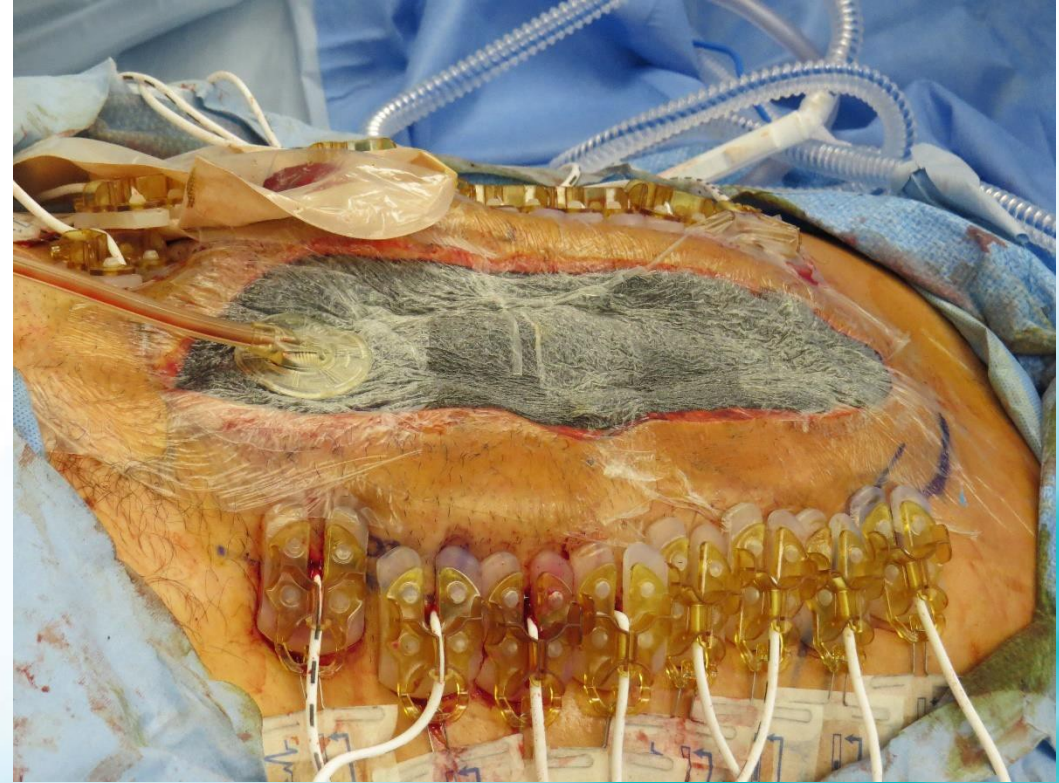
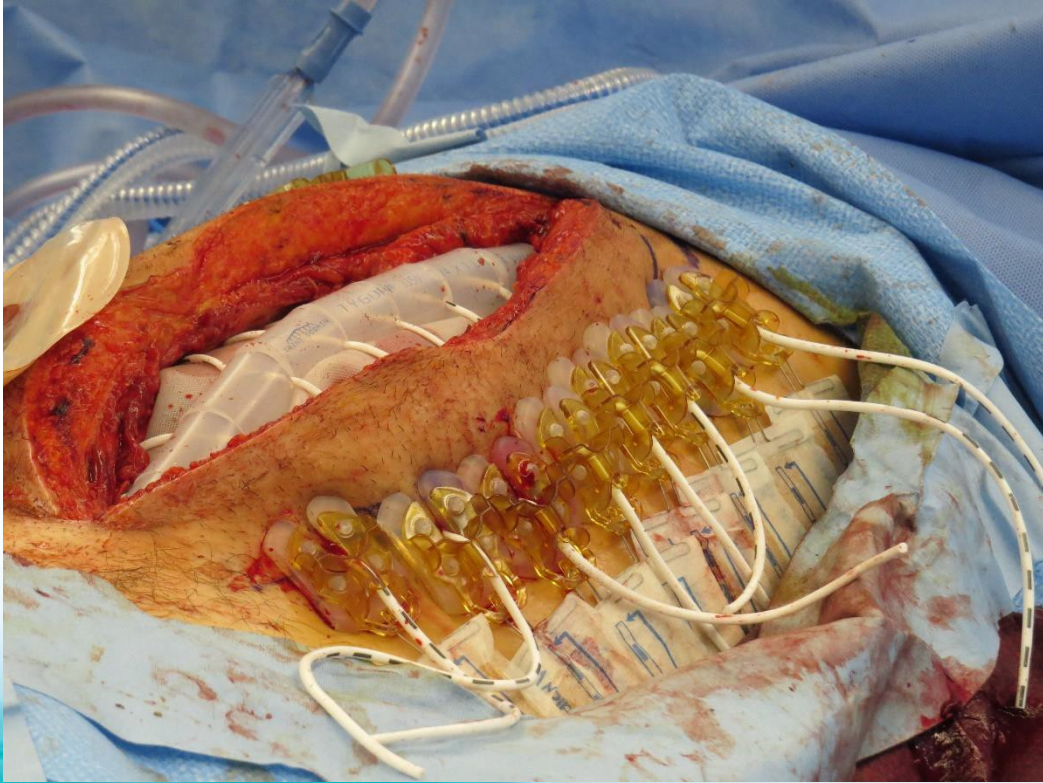
BRITISH COLUMBIA, CANADA

This is a case of a 39 year old male who sustained sharp trauma to the neck with injury to the carotid artery. Vigorous and sustained resuscitation caused Abd Compartment Syndrome, which soon thereafter resulted in bowel ischemia. Emergency laparotomy with Colectomy ensued with resulting open abdominal wound. First course of treatment was with ABthera followed by ABRA.

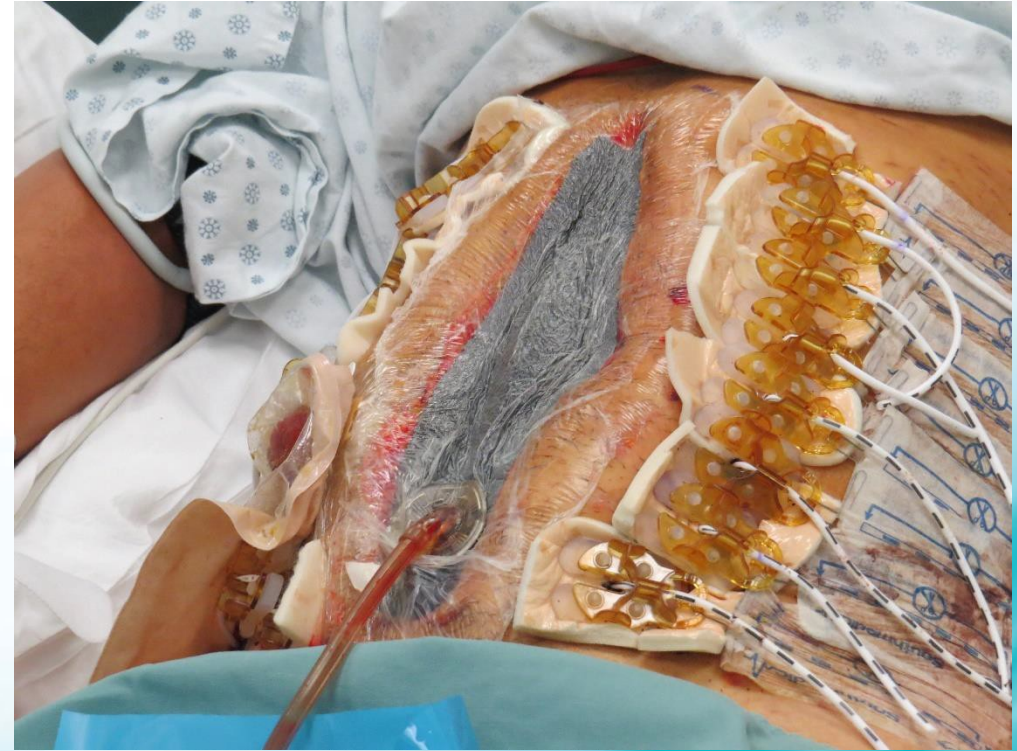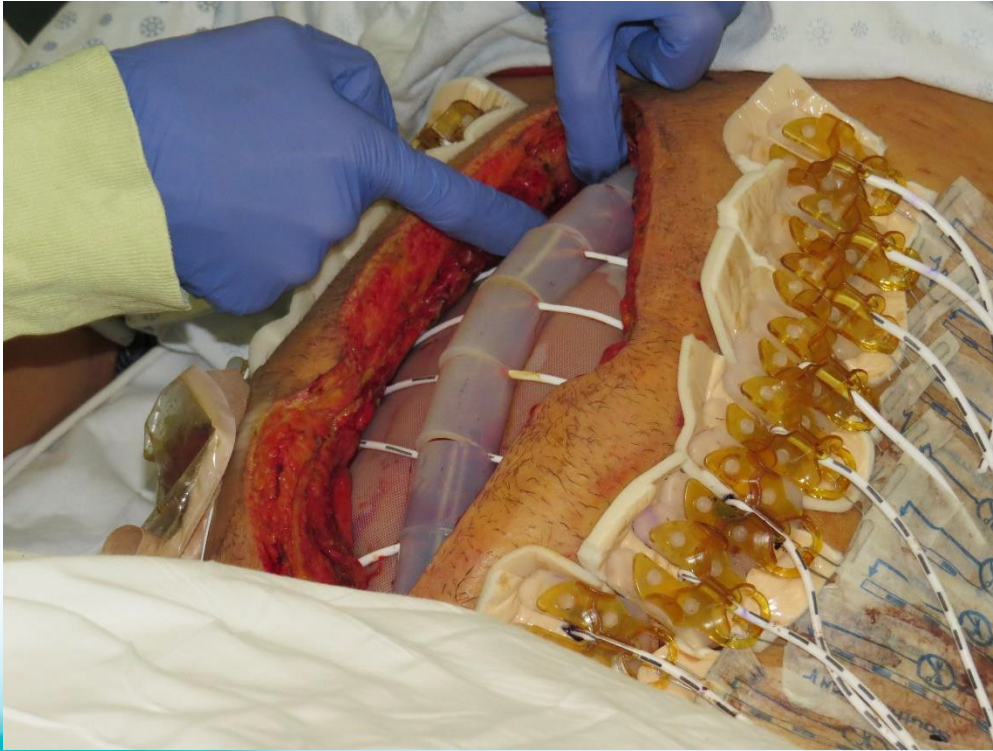ABRA INSTALLATION AUGUST 28TH



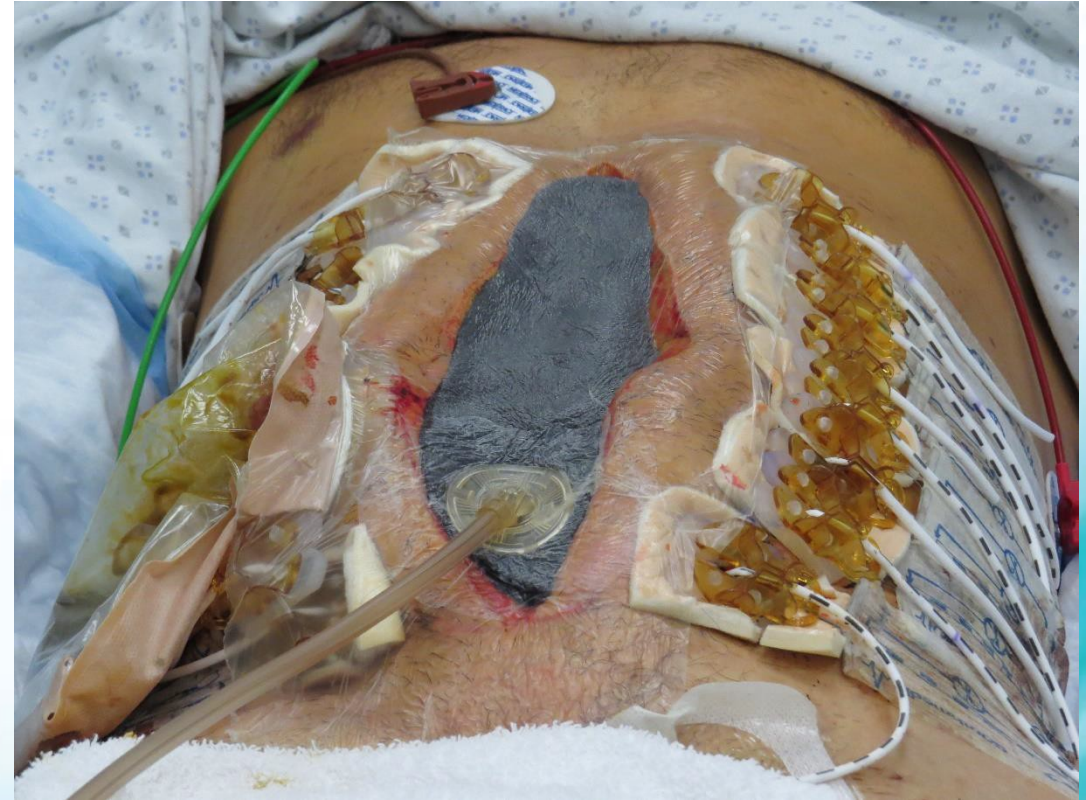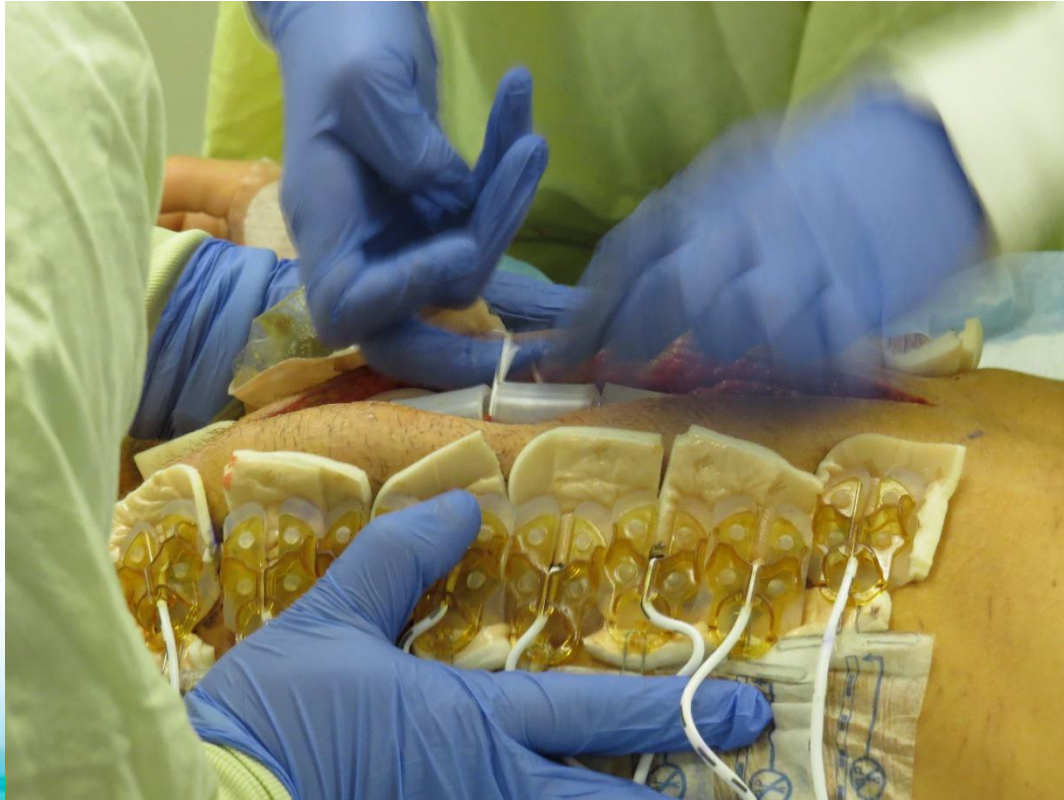ABRA INSTALLATION AUGUST 28TH



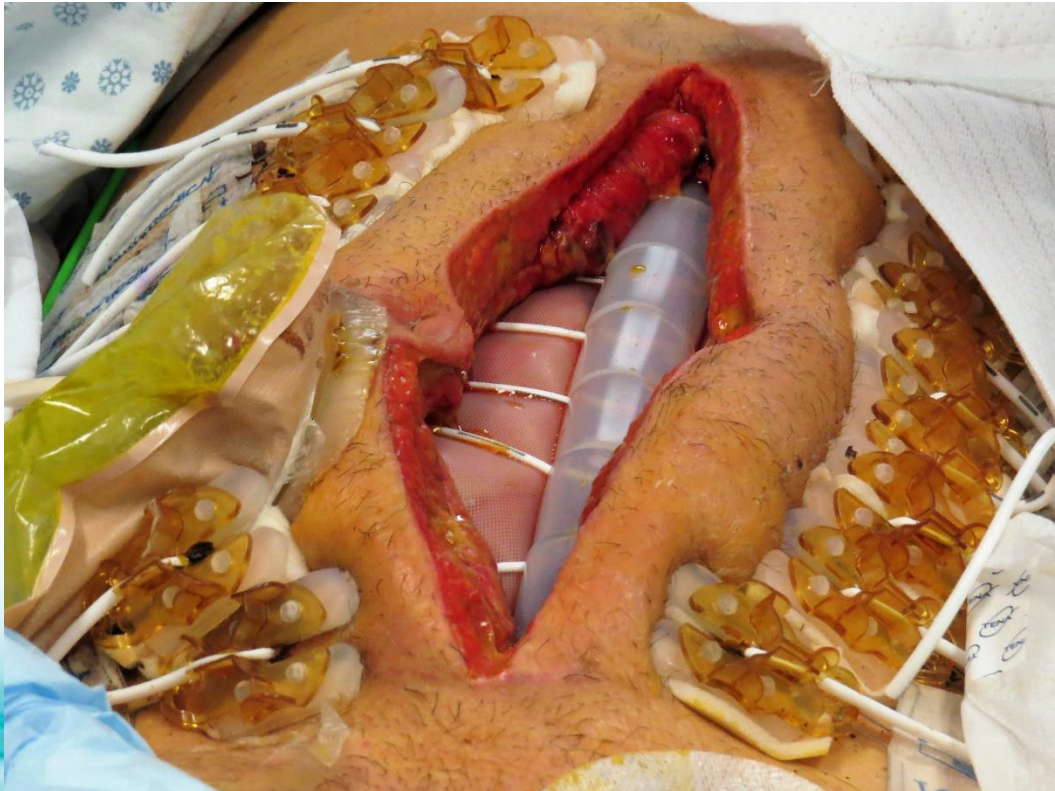
ABRA ADJUSTMENT DAY 3 POST INSTALLATION



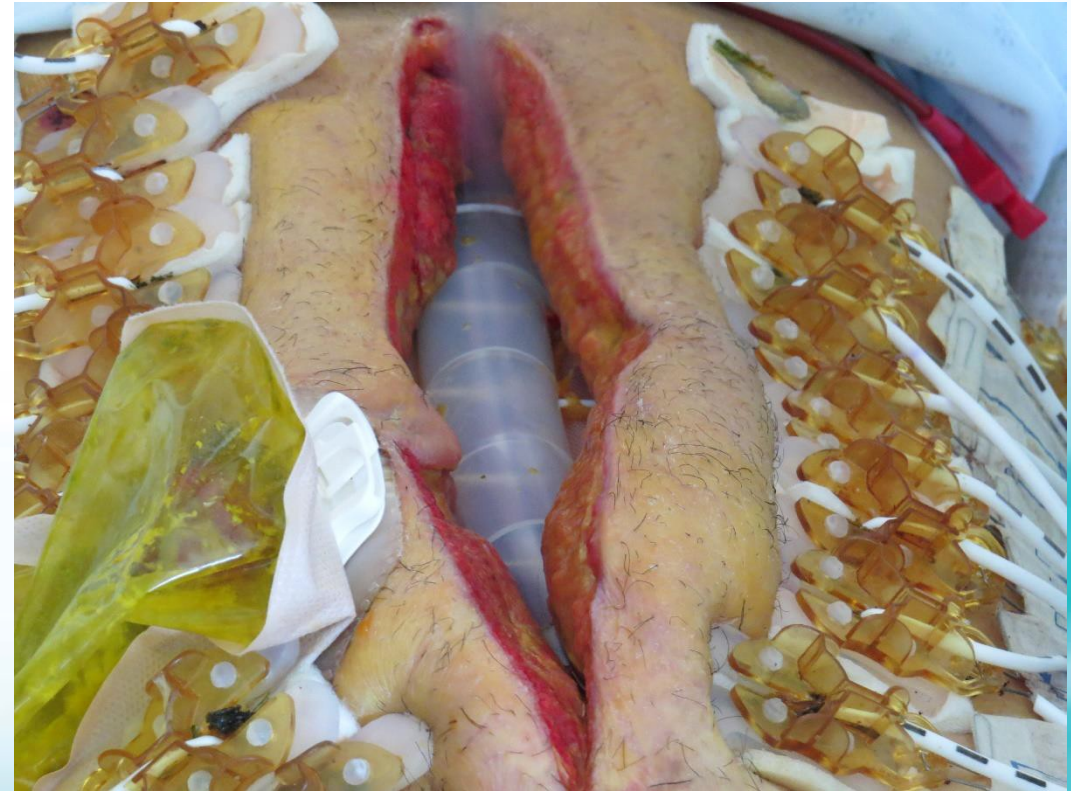ABRA ADJUSTMENT DAY 6 POST INSTALLATION



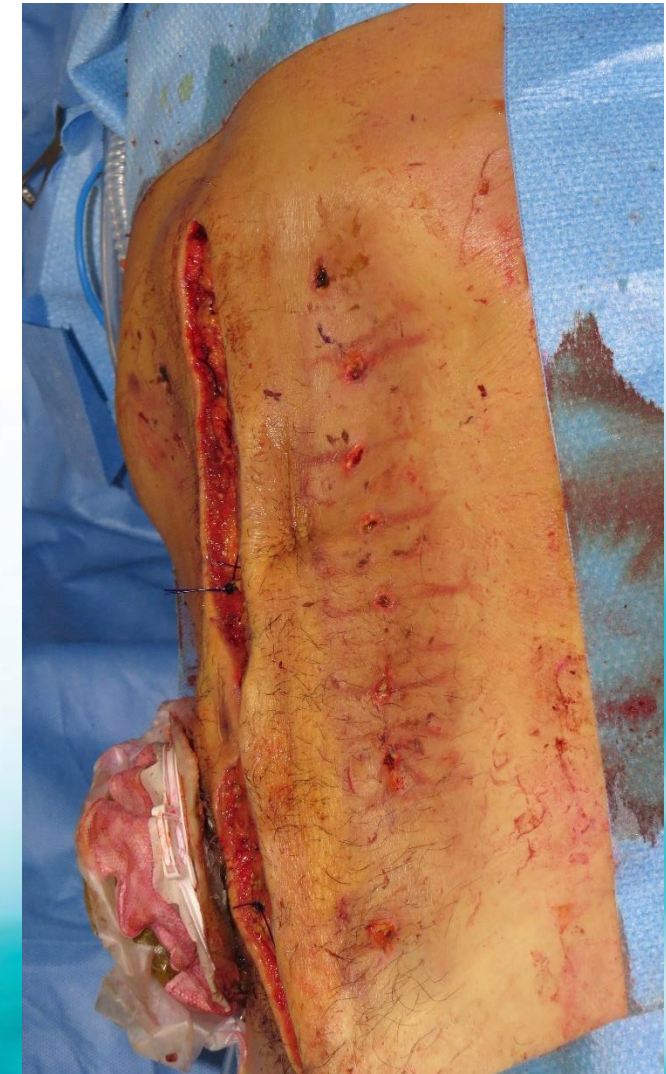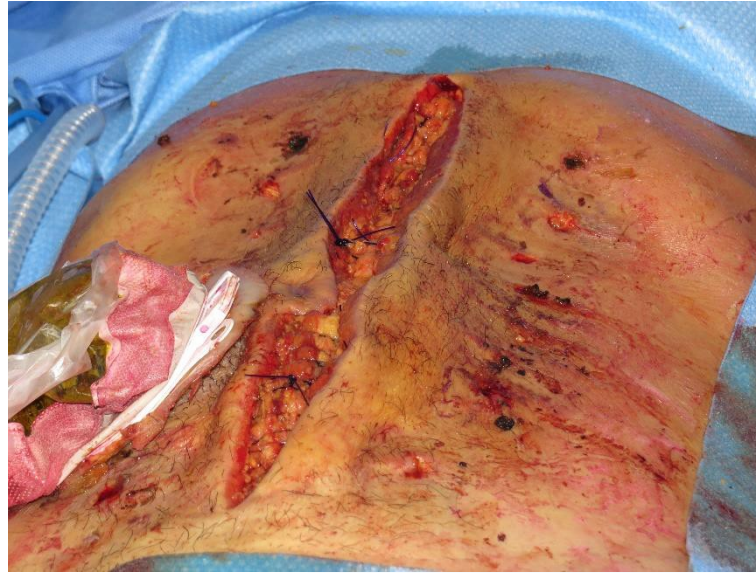
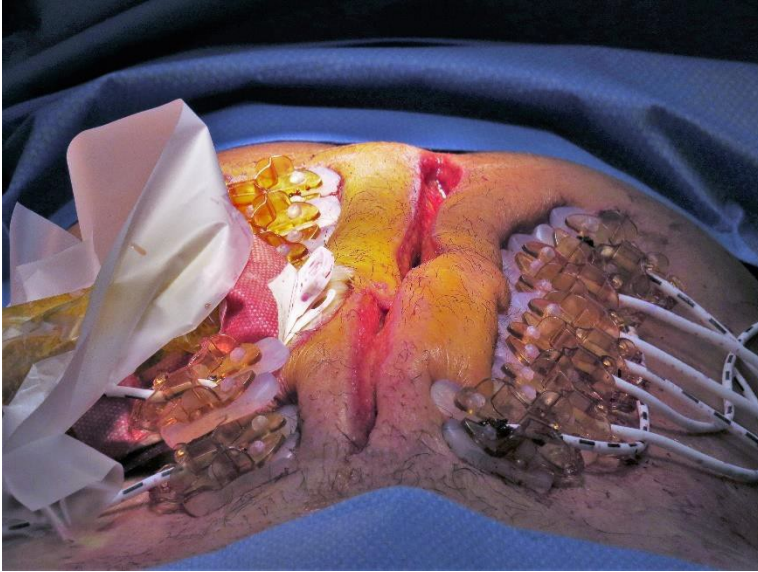
ABRA DAY 11 POST INSTALLATION



ABRA DAY 14 POST INSTALLATION



CLOSURE DAY 17 POST INSTALLATION



BECAUSE OF EXISTING RISK OF INFECTION THE SKIN WOUND WAS TREATED WITH NWPT FOR A PERIOD OF TIME AND LEFT TO CLOSE BY SECONDARY INTENTION.